

PENTAX i-SCAN™ with Anal Cancer

Patient History

A 69-year-old male was referred for routine surveillance colonoscopy. He denied any symptoms of bright red blood per rectum or any rectal pain or discharge. His family history was positive with his father having being diagnosed with colorectal cancer at age 78 years. The patient had one prior colonoscopy 5 years earlier that demonstrated a small tubular adenoma.

Colonoscopy Findings:

A small sessile polyp was found in the sigmoid colon and was removed with "Cold" snare polypectomy. The pathology was consistent with a tubular adenoma.

Retroflexion exam in the rectum appeared normal. However, in the forward view as the colonoscope was withdrawn, in the anorectum, just at the dentate line, colonoscopy with white light endoscopy (WLE) suggested mucosal irregularity (Figure 1). The i-SCAN 1 mode was switched on and revealed a small erythematous, friable, ulcerated nodular lesion in the distal ano-rectum in the posterior wall (Figure 2.1, 2.2, 2.3). This area was targeted for biopsy and the histopathology revealed squamous cell cancer of the anal canal (Figure 3 pathology).

Patient Follow-up and Outcome:

The patient subsequently underwent R-US (Rectal Endoscopic Ultrasound) which revealed a 1.4 cm x 2.1cm lesion in the distal anorectum c/w anal cancer stage: T2N0. He was then referred to combined multi-disciplinary colo-rectal surgery and oncology clinic and under went therapy with chemo/ radiation with successful response.

Deepak V. Gopal, MD, FRCP(C), AGAF, FACG, FASGE
Professor of Medicine
Director of Endoscopy,
Division of Gastroenterology
Univeristy of Wisconsin -
School of Medicine & Public Health
Madison, WI United States

Pathology contribution:
Rashmi Agni, MD
Associate Professor of Medicine
Department of Pathology &
Laboratory Medicine
Univeristy of Wisconsin -
School of Medicine & Public Health
Madison, WI United States

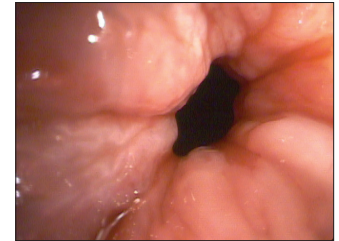


Figure 1

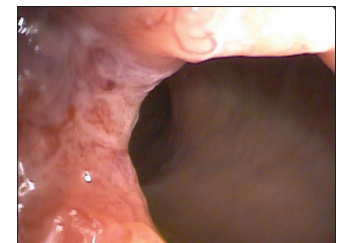

Figure 2.1

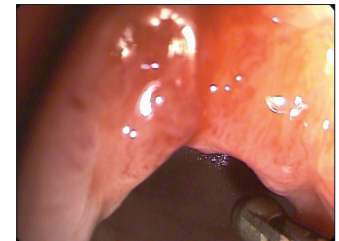


Figure 2.2

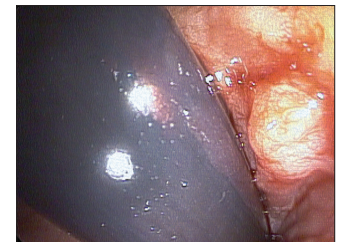


Figure 2.3

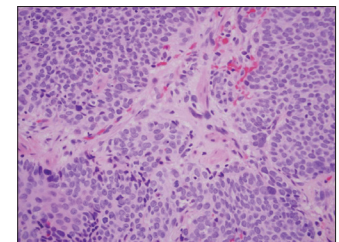


Figure 3

PENTAX Medical

3 Paragon Drive
Montvale, NJ 07645
Phone + 1 800 431 5880
Fax + 1 201 391 4189
www.pentaxmedical.com